



HEALTHY HEART

VOLUME-14 | ISSUE-166 | SEPTEMBER 05, 2023

Price : ₹ 5/-

Honorary Editor :

DR MILAN CHAG

MD, DM (Cardiology), DNB (Cardiology)
FACC (Fellow of American College of Cardiology)
Interventional Cardiologist
Heart Failure and Heart Transplant Cardiologist
Structural Heart Disease and TAVI Specialist
Lipidologist and Preventive Cardiologist



Dear Friends,

Percutaneous Transluminal myocardial septal ablation (PTMSA) has emerged as a less invasive treatment of symptomatic patients with hypertrophic obstructive cardiomyopathy (HOCM). In the past three decade, the availability of this sophisticated technique has revived the interest of cardiologists in left ventricular outflow tract obstruction, which has led to the recognition that most patients with hypertrophic cardiomyopathy (HCM) have the obstructive type. Follow-up studies have already shown the safety and efficacy of the procedure, which offers symptomatic relief in most patients. Long-term survival is comparable to historical reports after surgical myectomy. Complications are rare and can be further reduced by an increase in the experience of the operators, while the theoretical concern for possible ventricular arrhythmogenicity caused by the myocardial scar has not been documented by the existing data. Although there are still no randomised trials, percutaneous septal ablation is a viable alternative for patients with HOCM. We have one of the largest series of such therapy in India (Table-4).

- Dr Milan Chag

HYPERTROPHIC OBSTRUCTIVE CARDIOMYOPATHY: ALCOHOL SEPTAL ABLATION- A PROVEN THERAPY NOW!

INTRODUCTION AND SALIENT FEATURES:

Hypertrophic cardiomyopathy (HCM) is a primary myocardial disorder which is clinically defined by the presence of unexplained left ventricular hypertrophy (Figure-1 & 2).

Figure-1

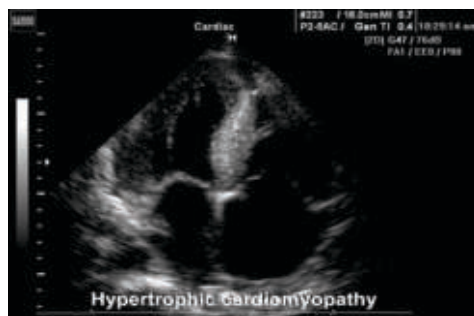
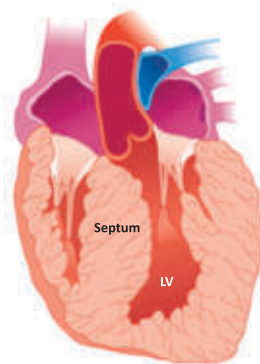


Figure-2



- The most common genetic cardiac disease, affecting 1 in 500 individuals.
- It is inherited as an autosomal dominant trait with variable penetrance, most commonly involving sarcomeric protein mutations.
- The disease can be diagnosed in patients of all ages and presents as asymptomatic individual to patients with severe symptoms of exertional dyspnoea or angina and reduced exercise capacity.
- The natural history of the disease may be highly heterogeneous with life expectancy ranging from normal longevity to sudden arrhythmic death (Table 1), often presenting at a young age, or evolution to congestive heart failure atrial fibrillation or stroke.
- Most patients present a characteristic left ventricular morphology with hypertrophy of the basal interventricular septum that is coupled with systolic anterior motion (SAM) of the anterior mitral valve leaflet and leads to

Cardiologists

Dr Vipul Kapoor (M) +91-98240 99848	Dr Urmil Shah (M) +91-98250 66939
Dr Tejas V. Patel (M) +91-89403 05130	Dr Hemang Baxi (M) +91-98250 30111
Dr Hiren Kevadiya (M) +91-98254 65205	Dr Anish Chandarana (M) +91-98250 96922
Dr Gunvant Patel (M) +91-98240 61266	Dr Ajay Naik (M) +91-98250 82666
Dr Keyur Parikh (M) +91-98250 26999	Dr Satya Gupta (M) +91-99250 45780
Dr Milan Chag (M) +91-98240 22107	Dr Vineet Sankhla (M) +91-99250 15056

Congenital & Structural Heart Disease Specialist

Dr Kashyap Sheth (M) +91-99246 12288	Dr Milan Chag (M) +91-98240 22107
--------------------------------------	-----------------------------------

Cardiothoracic & Vascular Surgeons

Dr Dhiren Shah (M) +91-98255 75933
Dr Dhaval Naik (M) +91-90991 11133
Dr Amit Chandan (M) +91-96990 84097
Dr Kishore Gupta (M) +91-99142 81008
Dr Nikunj Vyas (M) +91-73531 65955

Paediatric & Structural Heart Surgeons

Dr Shaunak Shah (M) +91-98250 44502

Cardiovascular, Thoracic & Thoracoscopic Surgeon

Dr Pranav Modi (M) +91-99240 84700

Cardiac Anaesthetists

Dr Niren Bhavsar (M) +91-98795 71917
Dr Hiren Dholakia (M) +91-95863 75818
Dr Chintan Sheth (M) +91-91732 04454

Cardiac Electrophysiologist

Dr Ajay Naik (M) +91-98250 82666
Dr Hiren Kevadiya (M) +91-98254 65205



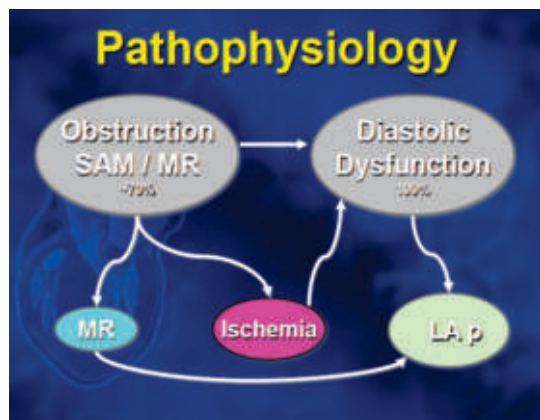
Table-1 Risk Factors For Sudden Cardiac Death

1. Familial sudden death
2. Unexplained syncope
3. Multiple, repetitive NSVT (Holter)
4. Abnormal exercise response
5. Massive LVH Septal thickness > 30 mm
6. Cardiac arrest survivors
7. Documented sustained ventricular tachycardia
8. Cardiac MRI: >15% area with LGE

dynamic left ventricular outflow tract (LVOT) obstruction and mitral regurgitation due to malcoaptation of the mitral leaflets.

- Symptomatic status depends on left ventricular obstruction, diastolic dysfunction and myocardial ischaemia. The existence of significant obstruction at rest or after provocation is associated with symptomatic status and has significant prognostic implications. (Figure-3)

Figure-3



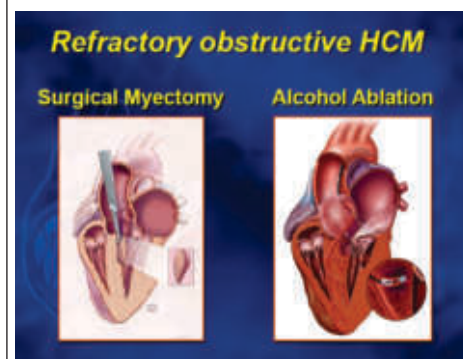
MANAGEMENT:

- In general, treatment of patients with hypertrophic cardiomyopathy aims at relieving symptoms, reducing the risk of sudden death and offering genetic counselling.

- Consequently, treatment of symptomatic patients with obstructive HCM (HOCM) aims at the reduction of the pressure gradient. Medical treatment with β -blockers, disopyramide or verapamil, are first line therapy but some patients remain symptomatic in spite of them. Mavacamten (cardiac myosin inhibitor) is a novel new agent. It has shown significant improvement in symptoms, hemodynamics and cardiac remodeling on short term follow up, Reduction in LVFE due to it needs regular monitoring.
- In drug-refractory patients, alcohol septal ablation (Percutaneous Transluminal Septal Myocardial Ablation-PTSMA) (Figure-4)

has emerged as a less invasive treatment than surgery to reduce LVOT obstruction by creating an infarction limited to the part of the basal septum, involved in the development of LV obstruction (Table-2).

Figure-4



PROCEDURE (PTSMA)

- Under local anesthesia and prophylactic transjugular temporary pacemaker lead insertion, first septal artery is identified and OTW balloon

Table-2 : INDICATIONS FOR SEPTAL REDUCTION (PTSMA) TREATMENT:

CLINICAL INDICATION

- Symptomatic patients
 - ☐ Drug-refractory or severe side effects of drugs
 - ☐ Functional class III and IV or functional class II with objective exercise limitations
 - ☐ Recurrent exercise-induced syncope
- Failure of prior myectomy or pacemaker
- Comorbidity-related increased surgical risk

HAEMODYNAMIC INDICATION

- Intracavitary gradient >30 mmHg at rest and/or
- Provocable gradient >50 mmHg

MORPHOLOGIC INDICATION

- Echocardiography
 - ☐ Subaortic, HCM with SAM-associated gradient
 - ☐ Exclusion of intrinsic mitral valve apparatus disorders
- Coronary angiography
 - ☐ Suitable septal branch

of appropriate size is placed over the guide wire in the artery to occlude it completely. After confirming the target septal tissue by contrast echocardiography, 1 to 3 ml of absolute alcohol (1 ml/ 1 cm of IVS) is injected in target septal artery through central lumen of OTW balloon catheter under continuous ECG and hemodynamic monitoring. At the end, balloon catheter is removed, check angiogram is done and patient is monitored in CCU for 48 hours. (Figure-5, 6)

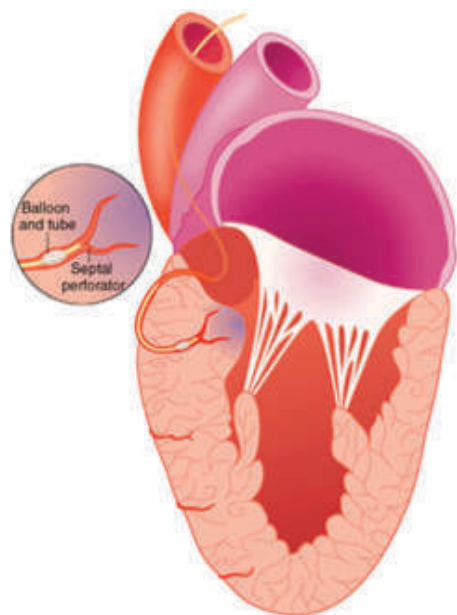


Figure-5 : Procedure (PTSMA)

PATHOPHYSIOLOGICAL EFFECTS OF SEPTAL ABLATION:

- Injection of alcohol during the procedure causes coagulative necrosis of the targeted myocardium and the septal micro vasculature.
- Tissue oedema appears early in this process, while muscle replacement

Figure-6 : Procedure (PTSMA)

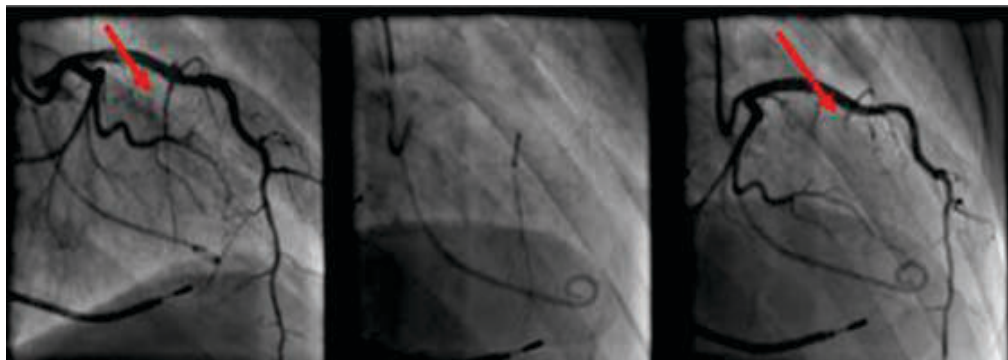


Figure-7

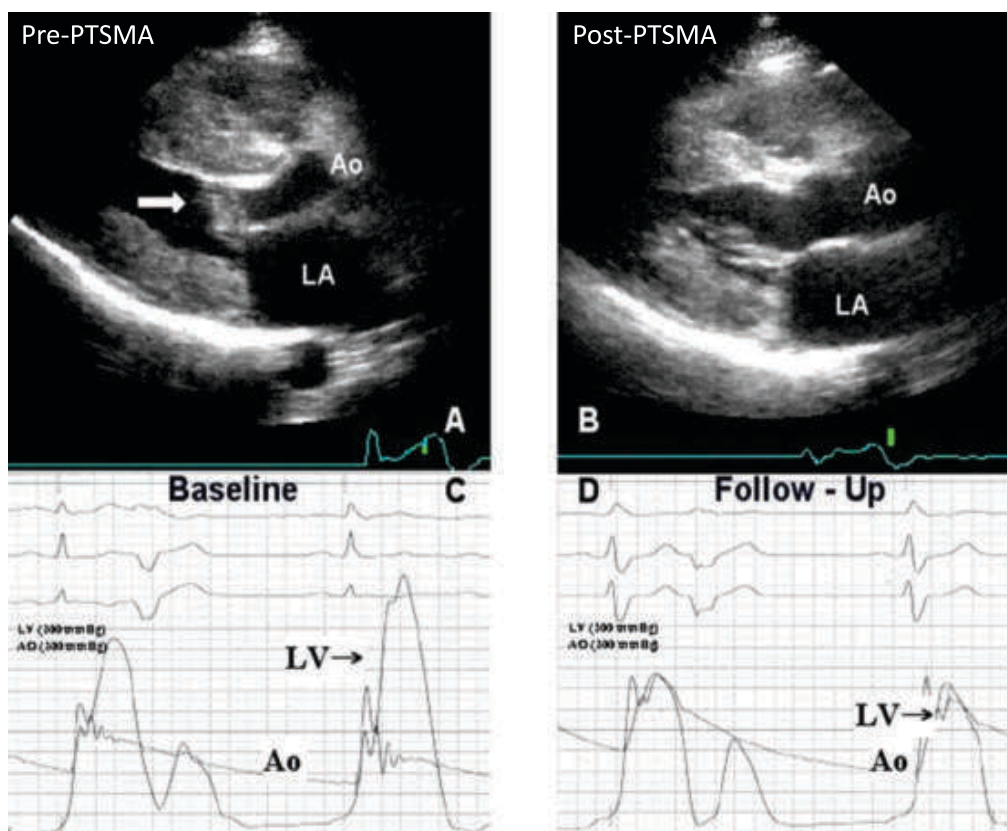


Figure-8

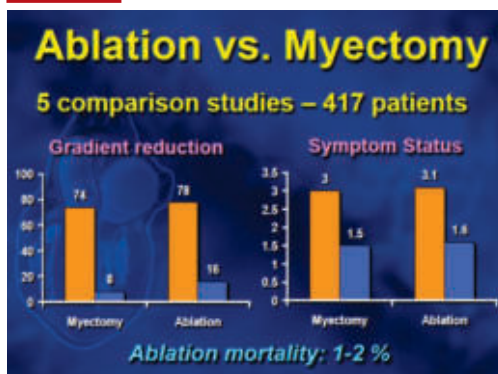
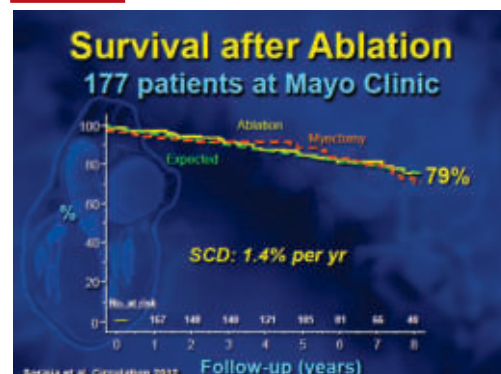


Figure-9





by scar formation develops only after several days.

- Thinning of the ablated area and scar formation lead to a permanent and significant reduction of the obstruction and the associated mitral regurgitation within the next 6-12 weeks.

CLINICAL RESULTS

- Haemodynamic success with reduction in both resting and provokable gradients is accomplished in $\geq 90\%$ of patients and is associated with significant improvement in symptoms (Figure-7,8).
- Mean NYHA class decreased from 2.9 to 1.2 and mean CCS class decreased from 1.9 to 0.4 at 1-year follow-up. Exercise capacity also improved on a treadmill. In a cohort of the first 99 consecutive patients treated the overall survival was 98% at 12 years, while 80% of patients

Table-3 : Comparison of Septal Myectomy and Percutaneous Alcohol Septal Ablation

Parameter	Percutaneous Alcohol Septal Ablation	Surgical Myectomy
Invasiveness	Percutaneous access	Sternotomy
Onset of reduction in LVOT	Maximam decrease in gradient instantly,	
Instantaneous		
gradient	And by 6 to 12 week	
Success rate (%)	>90%	>90%
Procedural mortality (%)	<1%	2-10%
Recovery time	2-4 days	2 week
Effect on LVOT gradient	Decreases to <20 mm Hg	Decreases to <10 mm Hg
Postprocedure conduction abnormality (commonest)	Right bundle branch block	Left bundle branch block
Need for permanent pacemaker-all patients (%)	5%	3-10%
Length of follow-up (year)	15-20	30

remained free of severe symptoms, atrial fibrillation, and stroke or ICD implantation. Results of last 12 years are comparable to published literature (Table-3, Figure-9)

CONCLUSIONS

Alcohol septal ablation has emerged in the last 20 years as a less invasive alternative to the standard surgical

treatment of symptomatic patients with HOCM. The accumulated long-term results have shown an ongoing relief of symptoms in the majority of patients. Hospital mortality can be practically eliminated in experienced centers, while the need for permanent pacing has also been reduced with increased experience.

Table-4 : Results

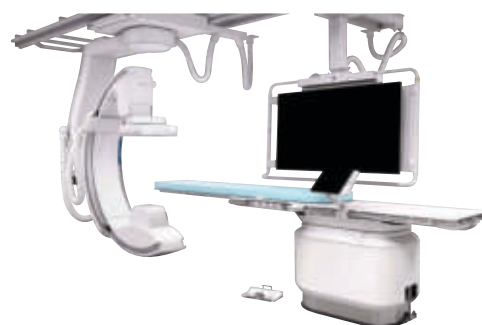STUDY	NO. OF PATIENTS	AGE (YEARS)	PACEMAKER IN-HOSPITAL (%)	MEN FOLLOW-UP TIME (YEARS)	IN-HOSPITAL MORTALITY (%)	LONG-TERM ALL-CAUSE MORTALITY (%)	REDO PROCEDURES (%)	MYECTOMY (%)	SURVIVAL	SURVIVAL WITHOUT SYMPTOMS
Seggewiss 2007	100	52.7±15.7	8	4.8±1.2	1	3			96%@8y	74 %
Welge 2008	347	54±15	7	4.8±2.9	1	8	5	3	92%	74 %
Sorajja 2008	138	64±21	20	2.2±2.8	1.4	8	4		88%@4y	76.4 %
Kuhn 2008	329	58±15	17	2.1	1.8	7	13		91.1%	
Fernandes 2008	619	53.9±15.0	8.2	4.6±2.5	1	8	14	25	89%@8y	
Kwon 2008	55	63±13	25.5	8±1	0	24	5.5	5	76%@10y	
Noseworthy 2009	89			5.0±2.3		9	10	11	91%	
Ten Cate 2010	91	54±15	4	5.4±2.5	2	10	5	5	88%	
Lyne 2010	12	69±22	0	11.75	0	3	17	0		73%@10y
Chag MC 2023	99	46±12	3	12.4	0	2	2	0	98 %	80 %



INSTITUTE OF CARDIAC SCIENCES

Marengo CIMS Hospital, Ahmedabad

4th and Most Versatile Cath Lab
“Azurion 7C20 with Flexvision XI & 3 Dimensional Navix Precision Ep Mapping System”



Cardiac MRI | 4-D ECHO | CT Coronary Angiography | OCT | IVUS | FFR

Centre of Excellence for EP, PACEMAKERS, CRT-D, ICD, 3-D CARTO

INTERVENTIONAL CARDIOLOGY

Coronary Angiography | Coronary Angioplasty | Peripheral & Carotid Angioplasty | Device Therapy for Heart Failure | Balloon Valvuloplasty | Percutaneous Intervention for Structural Heart Diseases TAVI/TAVR | Electrophysiology Studies | Left Ventricular Assist Device (LVAD) Implantation

DISEASE-SPECIFIC CLINICS

Heart Transplant Clinic | CIMS STEMI Initiative | Structural and Valvular Clinic & STROKE Centre | CIMS Heart Failure Clinic | Arrhythmia Clinic | Cardio-Oncology Clinic



One of India's Largest Team of Heart Care Experts

TOP ROW LEFT TO RIGHT: Dr Vipul Ahir | Dhanyata Dholakia | Dr Chintan Sheth | Dr Niren Bhavsar | Dr Nikunj Vyas | Dr Shaunak Shah | Dr Dhiren Shah | Dr Dhaval Naik | Dr Amit Chandan | Dr Pranav Modi | Dr Kishore Gupta | Dr Hiren Dholakia | Ulhas Padiyar | Akash Rajawat | Dr Gunvant Patel

BOTTOM ROW LEFT TO RIGHT: Dr Tejas V. Patel | Dr Satya Gupta | Dr Urmil Shah | Dr Anish Chandarana | Dr Keyur Parikh | Dr Milan Chag | Dr Ajay Naik | Dr Hemang Baxi | Dr Hiren Kevadiya | Dr Vipul Kapoor | Dr Kashyap Sheth | Dr Vineet Sankhla



HEALTHY HEART

VOLUME-14 | ISSUE-166 | SEPTEMBER 05, 2023



Marengo CIMS
Hospital

JIC 2024

Joint International Conference

JANUARY 05 - 07

20th Annual Scientific Symposium 29th Year of Academics

JIC 2024
A 3 Day
Multi-speciality
Symposiums

**Internal
Medicine
Symposium**

**Cardio-
vascular
Symposium**

**Pulmonology
- Airway
Workshop**

**Cancer
CON**

**Gastro-
enterology
Update**

**Infectious
Diseases
Update**

**Neuro
Symposium**

**Gynaecology
and
Infertility
Update**

**Nephrology
Symposium**

Register for JIC 2024

And Get an Attractive Prize
(*For the First 500 Registrants,
Upto 30th September, 2023)

Don't Miss a Chance to Register Yourself

For MD Physicians

₹ 2,000/-* Only

For MD Students

₹ 1,000/-* Only

visit www.jicindia.org for more information

If you want to update your contact please email on : marengocims.communication@marengoasia.com

For Registration Information : M +91-90990 66538 | M +91-98251 08257

Conference Secretariat:

Marengo CIMS Hospital, Off. Science City Road, Sola, Ahmedabad - 380060.

(M) +91 - 90990 66538 | +91-98251 08257

Email : marengocims.communication@marengoasia.com | www.jicindia.org

Organized by

GMERS
Medical College,
Sola,
Ahmedabad

Supported by



CIMSRE

Care Institute
Medical Society
for Research
and Education

In Association with





JIC 2024
Joint International Conference
JANUARY 05 - 07

20th Annual Scientific Symposium
29th Year of Academics

REGISTRATION FORM - JIC 2024

PLEASE NOTE THAT IT IS MANDATORY TO PROVIDE ALL THE INFORMATION.

PLEASE FILL IN CAPITAL LETTERS

FOR MD PHYSICIANS
₹ 2,000/-
*
Only

FOR MD STUDENTS
₹ 1,000/-
*
Only

Full Name : _____
Qualification : _____
Speciality : _____
Resi. Address : _____
City : _____ Pin Code : _____
Mobile No. : _____
Email : _____

Cheque or DD's to be made A/C payee and in the name of
'CIMS Hospital Pvt. Ltd.' Kindly mail the cheque/DD to our office.

Note : Hotel Accommodation is optional. If you have applied for accommodation, please send a separate deposit cheque of ₹ 5000 to cover the cost of your stay for two nights. Spouse hotel registration will be charged extra. Students also need to pay for Hotel Accommodation at the same rate. If physical conferences is

PAYMENT DETAILS

₹ : _____ in words : _____

DD/Cheque : _____ Date : ____ / ____ / ____

FOR REGISTRATION INFORMATION

(M) +91-90990 66538

(M) +91-98251 08257

Organized by

GMERS
Medical College,
Sola,
Ahmedabad

Supported by



Care Institute
Medical Society
for Research
and Education

In Association with



Conference Secretariat

Marengo CIMS Hospital, Off. Science City Road, Sola, Ahmedabad - 380060
(M) +91-90990 66538 | +91-98251 08257
Email : marengocims.communication@marengoasia.com | www.jicindia.org



HEALTHY HEART

VOLUME-14 | ISSUE-166 | SEPTEMBER 05, 2023

Healthy Heart Registered under **RNI No. GUJENG/2008/28043**

Published on 5th of every month

Permitted to post at PSO, Ahmedabad-380002 on the 12th to 17th of every month under
Postal Registration No. **GAMC-1725/2021-23** issued by SSP Ahmedabad valid upto 31st December, 2023
Licence to Post Without Prepayment No. **PMG/NG/055/2021-23** valid upto 31st December, 2023

If undelivered please return to :

Marengo CIMS Hospital,
Nr. Shukan Mall, Off Science City Road,
Sola, Ahmedabad-380060.
Call : 1800 309 9999

Subscribe "Healthy Heart" : Get your "Healthy Heart", the information of the latest medical updates only ₹ 60/- for one year.
To subscribe pay ₹ 60/- in cash or cheque/DD at CIMS Hospital Pvt. Ltd. Nr. Shukan Mall, Off Science City Road, Sola,
Ahmedabad-380060. Phone : +91-79-4805 2823. Cheque/DD should be in the name of : **"CIMS Hospital Pvt. Ltd."**
Please provide your **complete postal address with pincode, phone, mobile and email id** along with your subscription

JIC 2024
Joint International Conference
JANUARY 05 - 07

DO NOT MISS

20th Annual Scientific Symposium | 29th Year of Academics

SUPER EARLY BIRD PRIZE*

Register for JIC 2024

UPTO SEPTEMBER, 2023

And Get an Attractive Prize
(*For the First 500 Registrants Only)

For MD Physicians
₹ 2,000/-* Only

For MD Students
₹ 1,000/-* Only

Marengo CIMS Hospital : Regd Office: Plot No.67/1, Opp. Panchamrut Bungalows, Nr. Shukan Mall, Off Science City Road, Sola, Ahmedabad - 380060.
Ph. : +91-79-2771 2771-72 | 4805 1111

CIMS Hospital Pvt. Ltd. | CIN : U85110GJ2001PTC039962 | marengocims.info@marengoasia.com | www.cims.org

Printed, Published and Edited by Dr. Keyur Parikh on behalf of the Marengo CIMS Hospital
Printed at Hari Om Printery, 15/1, Nagori Estate, Opp. E.S.I. Dispensary, Dudheshwar Road, Ahmedabad-380004.
Published from Marengo CIMS Hospital, Nr. Shukan Mall, Off Science City Road, Sola, Ahmedabad-380060.