



HEALTHY HEART

VOLUME-14 | ISSUE-165 | AUGUST 05, 2023

Price : ₹ 5/-

Honorary Editor :

DR KEYUR PARIKH

Interventional Cardiologist

Chairman of Marengo CIMS Hospital



Dear Friends,

As a healthcare provider, **Marengo CIMS Hospital** has taken giant steps in emerging as a leader in the industry with initiatives across various specialties. We have introduced several super-specialized initiatives to strengthen clinical excellence and provide the best treatment to our patients. With the launch of the most advanced and one-of-its-kind 4th cath lab, Marengo CIMS Hospital, Ahmedabad is the only private hospital in Gujarat, Rajasthan and Madhya Pradesh, and Western India, to have four cath labs. Marengo CIMS Hospital is also the first private hospital in Western India to have the most advanced and technologically skilled **Cathlab Azurion 7C20 with comprehensive features and state-of-the-art applications to treat various complex procedures like, Coronary Angiography, Angioplasty, PAMI, Acute Stroke, 3D EP Mapping, Carotid Angioplasty, etc.** This is a technology taking interventional therapy to the next level.

Due to the presence of a Flex C-type arm of the machine, the system ensures that doctors can access both 2D and 3D images of the body without the need for separate CT Scan or MRI facilities. As the clinician operates the machine, it automatically changes the alignment with the patient, for accurate visualization and enabling consultants to keep their focus on the treatment, improving diagnostic accuracy.

Angiography has been the gold standard for imaging during Percutaneous Coronary Interventions/Angioplasty for the last many years but it has many limitations. We, at Marengo CIMS Hospital, now use highly advanced imaging catheter-based intravascular techniques such as the latest **Intravascular Ultrasound (IVUS) and Optical Coherence Tomography(OCT)** to optimize clinical outcomes.

In this update, we discuss the current applications of the available imaging techniques.

What Physicians Need to Know about OCT, FFR and IVUS

Introduction

Coronary angiography remains the most commonly used imaging modality to describe the degree and extent of coronary atherosclerosis during diagnostic cardiac catheterization and percutaneous coronary intervention (PCI). Its accuracy is affected by technical limitations, important interobserver variability, and its poor visualization of the vessel wall. Furthermore, it provides limited information about the functional significance of the lesion.

Today, intravascular ultrasound (IVUS), fractional flow reserve (FFR), and optical coherence tomography (OCT) are extensively used to overcome the aforementioned limitations. Despite the increasing published data validating their

advantages, IVUS, FFR, and OCT remain largely underutilized.

Imaging technology and diagnostic tools for interventional cardiologists have changed dramatically over the past few years with the introduction of OCT, improvements in IVUS and pressure guide wires used in FFR. Product innovation and integration of these technologies, as well as a growing base of clinical evidence, are transforming the way physicians diagnose, treat and follow-up patients undergoing PCI. IVUS allows physicians to visualize lumen diameter and vessel walls from within the vessel, providing better guidance for stent placement. In Japan however, IVUS has reimbursement and is used in more than 70 percent of PCI procedures.

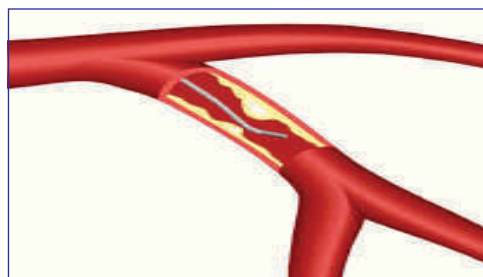


Fig. 1 - Fractional Flow Guide Wire®

Cardiologists

Dr Vipul Kapoor (M) +91-98240 99848	Dr Urmil Shah (M) +91-98250 66939
Dr Tejas V. Patel (M) +91-89403 05130	Dr Hemang Baxi (M) +91-98250 30111
Dr Hiren Kevadiya (M) +91-98254 65205	Dr Anish Chandarana (M) +91-98250 96922
Dr Gunvant Patel (M) +91-98240 61266	Dr Ajay Naik (M) +91-98250 82666
Dr Keyur Parikh (M) +91-98250 26999	Dr Satya Gupta (M) +91-99250 45780
Dr Milan Chag (M) +91-98240 22107	Dr Vineet Sankhla (M) +91-99250 15056

Congenital & Structural Heart Disease Specialist

Dr Kashyap Sheth (M) +91-99246 12288	Dr Milan Chag (M) +91-98240 22107
--------------------------------------	-----------------------------------

Cardiothoracic & Vascular Surgeons

Dr Dhiren Shah (M) +91-98255 75933
Dr Dhaval Naik (M) +91-90991 11133
Dr Amit Chandan (M) +91-96990 84097
Dr Kishore Gupta (M) +91-99142 81008
Dr Nikunj Vyas (M) +91-73531 65955

Paediatric & Structural Heart Surgeons

Dr Shaunak Shah (M) +91-98250 44502

Cardiovascular, Thoracic & Thoracoscopic Surgeon

Dr Pranav Modi (M) +91-99240 84700

Cardiac Anaesthetists

Dr Niren Bhavsar (M) +91-98795 71917
Dr Hiren Dholakia (M) +91-95863 75818
Dr Chintan Sheth (M) +91-91732 04454

Cardiac Electrophysiologist

Dr Ajay Naik (M) +91-98250 82666
Dr Hiren Kevadiya (M) +91-98254 65205

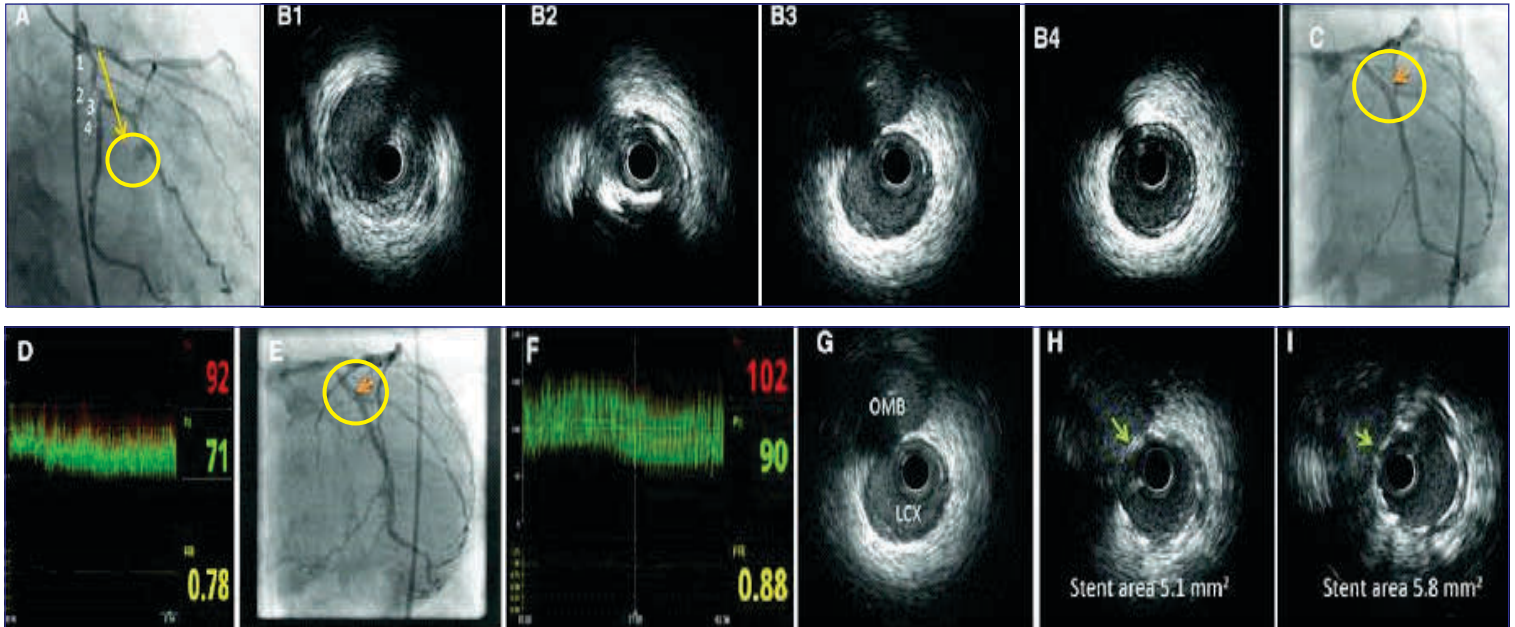


Fig. 2 - Intra Vascular Ultra Sound Image

Following are some advantages: of IVUS imaging:

- Three-dimensional view of a coronary artery.
- It gives cross-sectional imaging of the vessels.
- It provides enhanced tissue characterization, which allows detection and quantification of various plaque structure.
- It measures the degree of narrowing of an artery due to plaque.
- It can find the areas of external compression in a vein due to blood clots.
- It can detect the presence and proportion of calcifications, imaging helps identify stent necrotic tissues. or neoangiogenesis, and neovessel formation.
- IVUS imaging is effective in high-risk groups, including patients with diabetes, ACS. and Impaired Renal Function.
- Optimization and management of immediate complications during PCI, such as thrombus, dissection, or tissue. prolapse while surgery.
- With the help of IVUS, the surgeon can assess the risk of myocardial infarction and angiographic no-reflow during surgery.

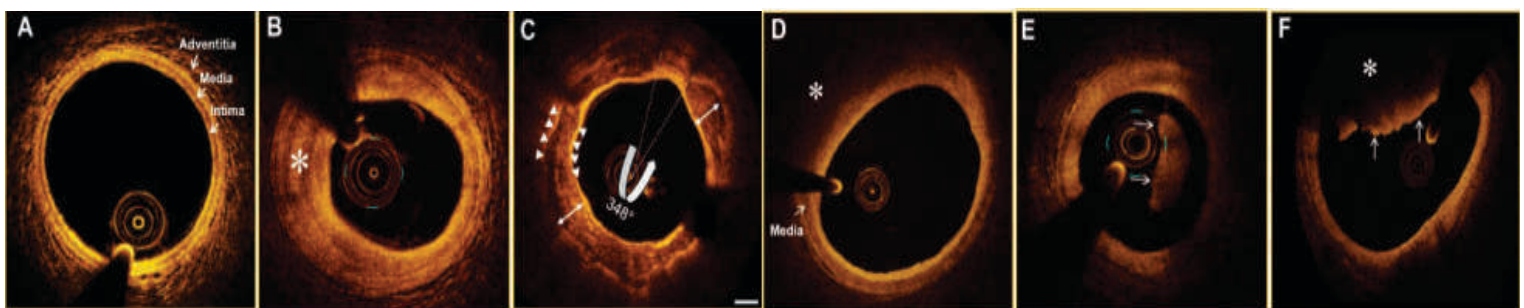
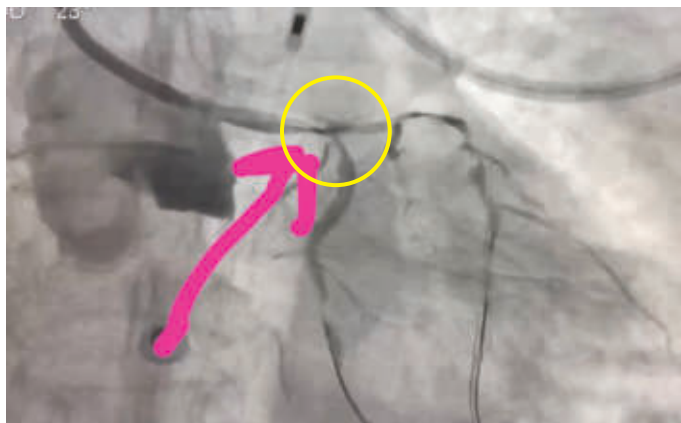


Fig. 3 - Optical Coherence Tomography

Imaging in High Risk Patient Useful or Not?



Critical Left Main Artery Narrowing into Origin of both Left Circumflex and Left Anterior Descending

History and Physical Examination

A 68 year - Male

Admitted with ACS and Heart Failure

ECHO: LVEF 25%

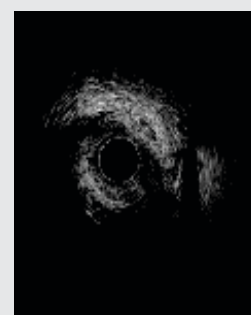
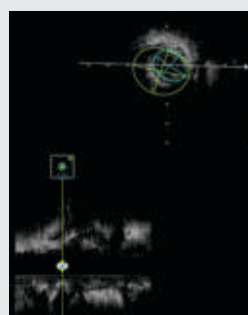
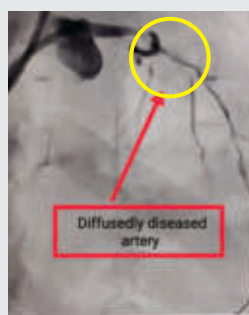Severe LV Dysfunction

Moderate to Severe MR

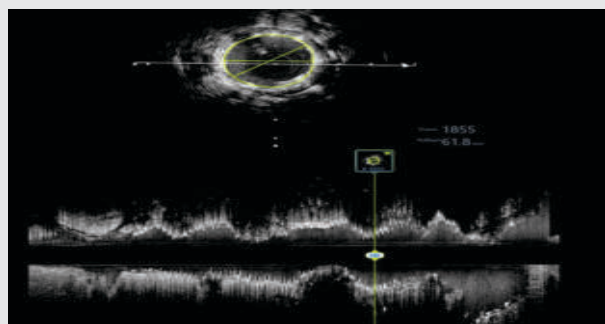
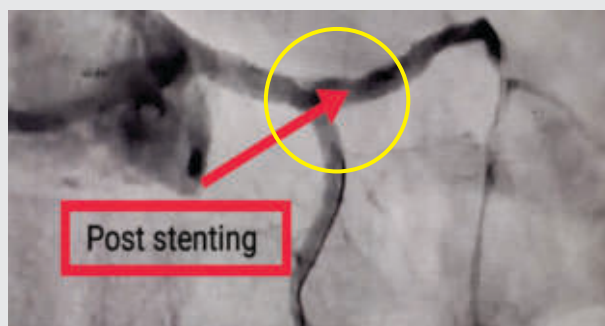
Critical LMCA with Triple Vessel Disease

Admitted for CABG in CIMS /Patient Deferred surgery

High Risk Consent for PCI



PRE LAD IVUS



POST LAD IVUS

Overview of Procedure

- Successful High risk Complex bifurcation PCI of LM, LAD and LCX with DES under IABP support
- Stented with Mid-Distal LAD with 48mm Stent and Distal LCX with 12mm Stent
- Patient is stable and Recuperating (Initially in SICU)
- IABP Removed
- Hemodynamically stable and Patient discharge

IVUS: useful tool to assess vascular geometry, plaque morphology before PCI, useful to assess post PCI tissue prolapse, stent underexpansion/ malaposition



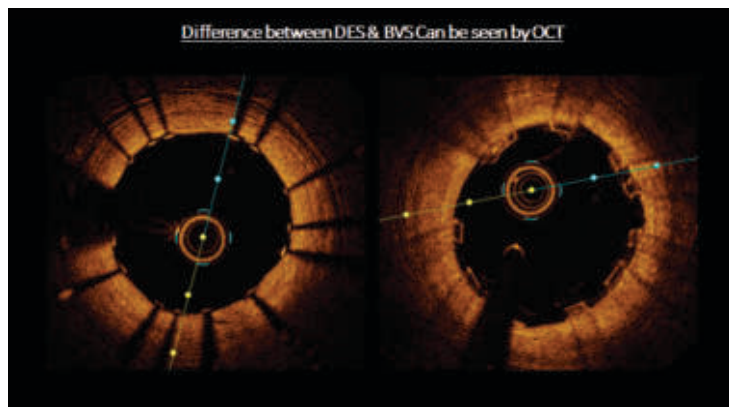
Novel Invasive OCT Imaging Makes Evaluation Easier & Life Saver

Technological innovations have created a revolution in the health care sector and changed the way how cardiac diseases are viewed and managed across the world.

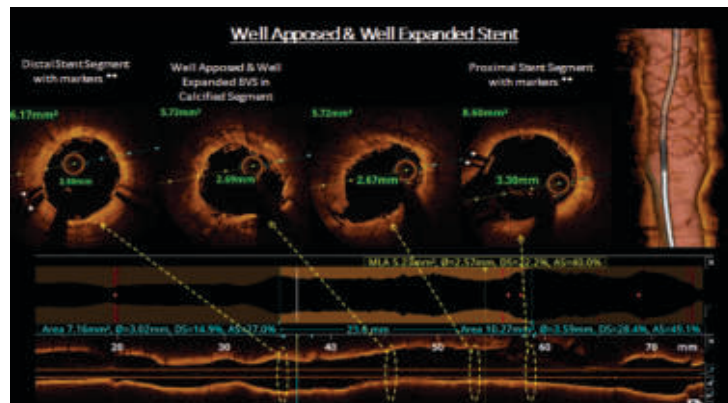
Cardiovascular medicine is undergoing radical changes day by day as a result of the vast number of resources being channeled into the field across the globe. Since the late 1990s, imaging in cardiovascular field has evolved from routine coronary angiography to computerized tomography [CT scan], cardiac magnetic resonance (MRI) and advanced echocardiography. Intravascular coronary imaging techniques like IVUS (intravascular ultrasound) & OCT (optical coherence tomography) has created a revolution in the field of coronary interventions for the betterment of patients.

New and improved intervention techniques are helping save lives and hastening recovery among cardiac patients. Technological advancements have made cardiac care far more effective and accessible to a lot more than it was a decade ago. OCT has improved the chances of recovery for patients with intense coronary blockages...

“What sets us apart is our clinical expertise and our evidence based, multidisciplinary treatment approach which is backed by the latest research and high-end medical technology usage”



“Usage of OCT in Cardiology Department of CIMS Hospital, is also one of the many steps taken to ensure optimal results even in the most complex cases and results in better patient outcomes.”



What is OCT?

Optical Coherence tomography (OCT) is a type of advanced medical imaging that uses light waves to take near-photographic quality cross-section pictures of living tissues. With OCT, doctors can obtain images of the blood vessels that are about the same as if they were looking under a microscope. The test, which received regulatory approval for cardiac use in India in the last decade, is usually performed as part of angiogram. In interventional cardiology, OCT imaging is used to take detailed images of blood vessel walls. These pictures are used to help determine the extent and burden of atherosclerotic plaques (build-up of cholesterol and other material) in a patient's arteries.

These plaques can build up and cause chest pain called angina. This detailed understanding can help an interventional cardiologists determine whether a stent is needed to treat the blockage and where to best place a stent so as to treat the blockage. After a stent has been placed, OCT can also be used to see how well the stent is covering the plaque and make certain it is expanded to the correct size for your vessel.

How does OCT work?

Most of us are already familiar with ultrasound, which uses sound waves to create images of internal structures in the body. OCT works similarly to ultrasound but uses infrared light instead of sound waves. In the case of OCT for cardiovascular procedures, an optical beam is directed at the tissue to be imaged and a small portion of this light that reflects from sub-surface features is collected. These signals are transmitted to a computer program that converts them to images of the blood vessel wall.

How does OCT benefit patients?

- OCT provides detailed images of superficial coronary plaque components. As per the histological analysis of autopsy specimens, there are 3 general plaque types: Fibrous, Fibro-calcific and Lipid Rich. All these plaque types can be accurately identified by OCT identifies plaque characteristics that predispose to rupture, including the thin fibrous caps, large lipid cores, and accumulation of macrophages.



Useful 3D Bifurcation Mode to Check Opening of Side Branches



Stent only Mode to Confirm Stent Optimization

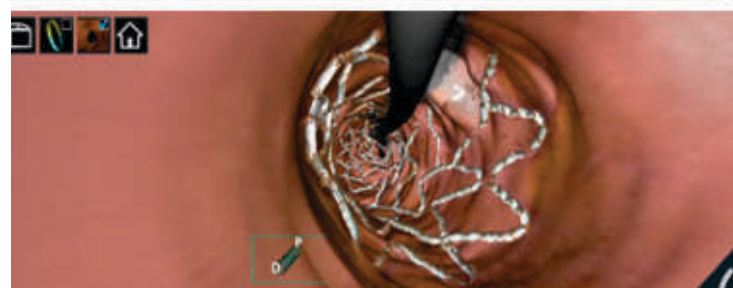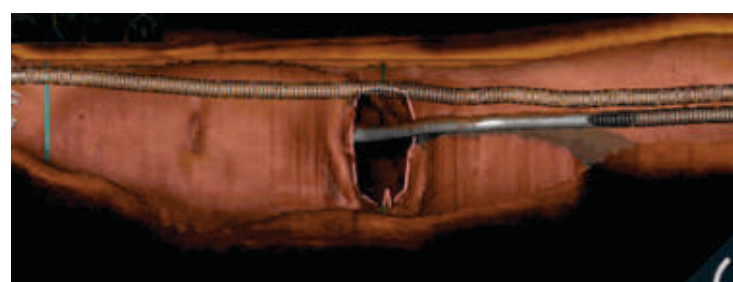
- OCT can provide critical information to guide coronary interventions, in addition to characterizing atherosclerotic plaques.
- OCT can be utilized to measure the reference vessel diameter, minimal luminal diameter, and length of the target lesion.
- OCT can be used to identify stent malapposition, tissue prolapse and both in-stent and edge dissection with higher sensitivity than IVUS.
- It is of specific benefit in assessing stent apposition with overlapping stents.
- It is utilized as a research tool to study coronary artery pathophysiology as well as response to endovascular interventions. In addition, it is also used to compare various stent platforms in terms of deployment, endothelialization and in-stent restenosis.
- OCT gives you real 3D reconstruction, which will be helpful during complex PCI, bifurcation PCI.

What are the applications of OCT?

The application of OCT in daily clinical practice can help in improving the outcomes for the patients and provide an Optimal Percutaneous coronary Intervention. OCT can help guide physicians on specific clinical situations and can help optimize physician treatment strategies. Some of the day to day practical applications can be as below:

- In-stent Restenosis
- Assessment of Calcified Lesions
- Thrombosis
- Stent Deployment and Edge Dissection
- Bifurcation Lesion Assessment and Percutaneous Coronary Intervention

“The addition of OCT to our imaging devices offers a more comprehensive array of imaging tools, enabling practitioners earlier and more effectively. OCT- guided procedures offer better procedural and in-hospital outcomes, and better long-term survival compared to standard angiography-guided interventional procedures. Increased adoption of OCT imaging, when combined with advanced technology like AI, allows cardiologists to have a more precise and measurable way of supporting patients undergoing coronary stent procedures. It can potentially improve physician systematic process, reducing variability and increasing accuracy of diagnosis and application of therapies”





HEALTHY HEART

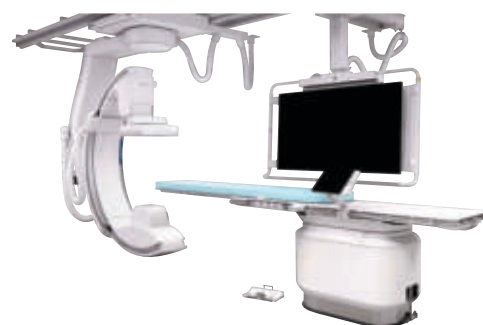VOLUME-14 | ISSUE-165 | AUGUST 05, 2023



INSTITUTE OF CARDIAC SCIENCES

Marengo CIMS Hospital, Ahmedabad

4th and Most Versatile Cath Lab
“Azurion 7C20 with Flexvision XI & 3 Dimensional Navix Precision Ep Mapping System”



Cardiac MRI | 4-D ECHO | CT Coronary Angiography | OCT | IVUS | FFR

Centre of Excellence for EP, PACEMAKERS, CRT-D, ICD, 3-D CARTO

INTERVENTIONAL CARDIOLOGY

Coronary Angiography | Coronary Angioplasty | Peripheral & Carotid Angioplasty | Device Therapy for Heart Failure | Balloon Valvuloplasty | Percutaneous Intervention for Structural Heart Diseases TAVI/TAVR | Electrophysiology Studies | Left Ventricular Assist Device (LVAD) Implantation

DISEASE-SPECIFIC CLINICS

Heart Transplant Clinic | CIMS STEMI Initiative | Structural and Valvular Clinic & STROKE Centre | CIMS Heart Failure Clinic | Arrhythmia Clinic | Cardio-Oncology Clinic



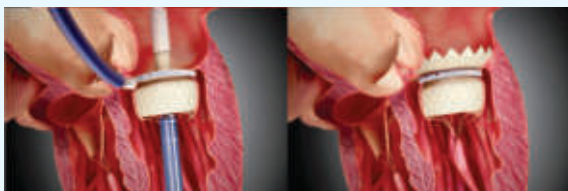
One of India's Largest Team of Heart Care Experts

TOP ROW LEFT TO RIGHT: Dr Vipul Ahir | Dhanyata Dholakia | Dr Chintan Sheth | Dr Niren Bhavsar | Dr Nikunj Vyas | Dr Shaunak Shah | Dr Dhiren Shah | Dr Dhaval Naik | Dr Amit Chandan | Dr Pranav Modi | Dr Kishore Gupta | Dr Hiren Dholakia | Ulhas Padiyar | Akash Rajawat | Dr Gunvant Patel

BOTTOM ROW LEFT TO RIGHT: Dr Tejas V. Patel | Dr Satya Gupta | Dr Urmil Shah | Dr Anish Chandarana | Dr Keyur Parikh | Dr Milan Chag | Dr Ajay Naik | Dr Hemang Baxi | Dr Hiren Kevadiya | Dr Vipul Kapoor | Dr Kashyap Sheth | Dr Vineet Sankhla

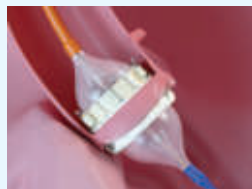

04th | TMVR
Transcatheter Mitral
Valve Replacement

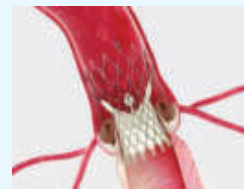


Balloon Expandable Valve

41st | TAVI
Transcatheter Aortic
Valve Implantation



Balloon Expandable
Valve



Self Expanding
Supra-Annular Valve

HIGHEST NUMBER IN GUJARAT


100% SUCCESSFUL HOSPITAL OUTCOMES

INDIA'S BEST HEART CARE EXPERTS

LEADER ACROSS INDIA IN TRANSPLANTS

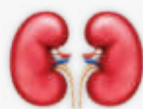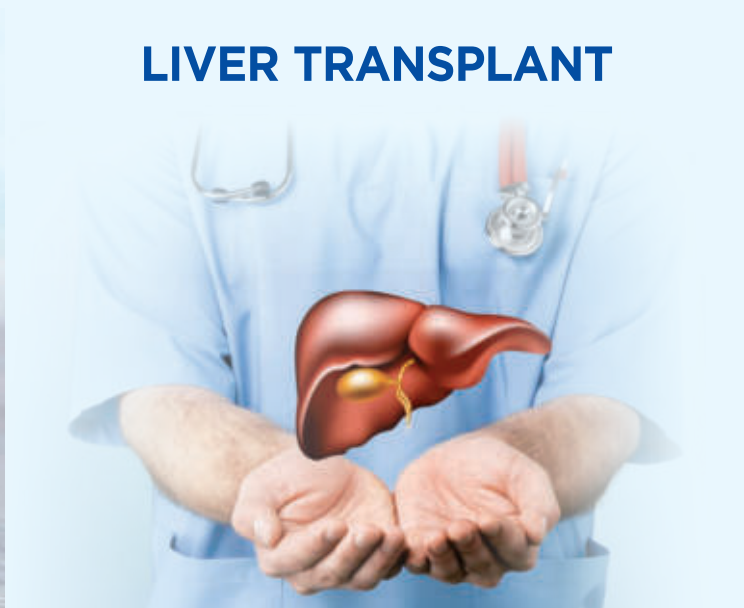42nd

HEART TRANSPLANT



46TH

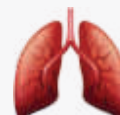LIVER TRANSPLANT



Kidney Transplant



Paediatric BMT



Lung Transplant



HEALTHY HEART

VOLUME-14 | ISSUE-165 | AUGUST 05, 2023

Healthy Heart Registered under **RNI No. GUJENG/2008/28043**

Published on 5th of every month

Permitted to post at PSO, Ahmedabad-380002 on the 12th to 17th of every month under

Postal Registration No. **GAMC-1725/2021-23** issued by SSP Ahmedabad valid upto 31st December, 2023

Licence to Post Without Prepayment No. **PMG/NG/055/2021-23** valid upto 31st December, 2023

If undelivered please return to :

Marengo CIMS Hospital,
Nr. Shukan Mall, Off Science City Road,
Sola, Ahmedabad-380060.
Call : 1800 309 9999

Subscribe "Healthy Heart" : Get your "Healthy Heart", the information of the latest medical updates only ₹ 60/- for one year.

To subscribe pay ₹ 60/- in cash or cheque/DD at CIMS Hospital Pvt. Ltd. Nr. Shukan Mall, Off Science City Road, Sola, Ahmedabad-380060. Phone : +91-79-4805 2823. Cheque/DD should be in the name of : **"CIMS Hospital Pvt. Ltd."**

Please provide your **complete postal address with pincode, phone, mobile and email id** along with your subscription

JIC 2024
Joint International Conference
JANUARY 05 - 07

DO NOT MISS

20th Annual Scientific Symposium | 29th Year of Academics

SUPER EARLY BIRD PRIZE*

Register for JIC 2024

UPTO AUGUST, 2023

And Get an Attractive Prize

(*For the First 500 Registrants Only)

For MD Physicians

₹ 2,000/* Only

For MD Students

₹ 1,000/* Only

Marengo CIMS Hospital : Regd Office: Plot No.67/1, Opp. Panchamrut Bungalows, Nr. Shukan Mall, Off Science City Road, Sola, Ahmedabad - 380060.

Ph. : +91-79-2771 2771-72 | 4805 1111

CIMS Hospital Pvt. Ltd. | CIN : U85110GJ2001PTC039962 | marengocims.info@marengoasia.com | www.cims.org

Printed, Published and Edited by Dr. Keyur Parikh on behalf of the Marengo CIMS Hospital

Printed at Hari Om Printery, 15/1, Nagori Estate, Opp. E.S.I. Dispensary, Dudheshwar Road, Ahmedabad-380004.

Published from Marengo CIMS Hospital, Nr. Shukan Mall, Off Science City Road, Sola, Ahmedabad-380060.